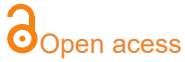

# Brenner's tumor associated with giant mucinous cystoadenoma: case report

Antônio Chambô Filho<sup>a</sup>, Carolina de Melo<sup>a</sup>, Isabella Bermudes Modenese<sup>a</sup>, Ronney Antônio Guimarães<sup>a</sup>.



<sup>a</sup>Escola Superior de Ciências da Santa Casa de Misericórdia de Vitória, EMESCAM.

#### Corresponding author

antonio.chambo@emescam.br

Manuscript received: may 2022

Manuscript accepted: december 2022

Version of record online: july 2023

#### Abstract

Brenner's tumor is a rare ovarian neoplasm, representing only 1-2% of ovarian neoplasms, most of which are benign tumors. It is defined as a fibroepithelial neoplasm derived from the ovarian stromal tissue and by epithelial cells of the urothelial or transitional type. They rarely have clinical manifestations, since they are small and unilateral. However, there are reports in the literature of tumors with large dimensions. In 25% of cases, Brenner's tumor may be associated with another type of ovarian tumor, such as mucinous, serous or endometrioid tumors. The conduct often consists only of excision of the tumor, in benign cases. However, if the tumor is malignant or suspected of malignancy, hysterectomy with bilateral salpingo-oophorectomy is preferred, complemented by omentectomy, pelvic lymphadenectomy, biopsy and peritoneal lavage.

**Keywords:** Brenner tumor; mucinous cystadenoma; ovarian neoplasm; ovary

**Como citar:** Filho AC, Melo C, Modenese IB, Guimarães RA. Brenner's tumor associated with giant mucinous cystoadenoma: case report. *Clinics Biopsychosocial*. 2023; 01(1):46-49. DOI: <https://doi.org/10.54727/cbps.v1i1.9>

## ● INTRODUCTION

Ovarian tumors can be derived from epithelial cells, these being the most frequent (95%). And less commonly, derived from germ and stromal cells. Ovarian epithelial neoplasms are classified, according to histological characteristics, into three groups: benign, malignant and low malignant potential tumors, also called borderline tumors<sup>1</sup>.

Benign ovarian epithelial tumors do not spread, and generally do not present with serious complications, being exemplified by serous cystadenomas, mucinous cystadenomas and Brenner's tumors<sup>1</sup>.

Brenner's tumor is a rare ovarian neoplasm, representing only 1-2% of ovarian neoplasms. Most of these tumors are benign (95%), and there are also borderline (3-4%), malignant (1%) and transitional cell carcinoma<sup>2</sup>.

It is defined as a fibroepithelial neoplasia derived from the ovarian stromal tissue and by epithelial cells of the urothelial or transitional type. These cells contain a small slit nucleus or "coffee bean"-shaped nucleus, and when they form groups, they form structures called niches or nests<sup>3</sup>.

Generally, Brenner tumors are small and unilateral, without clinical manifestations, therefore, incidental surgical findings. However, the largest ones can weigh up to 25 kg, with symptoms similar to those caused by large fibromas<sup>4</sup>.

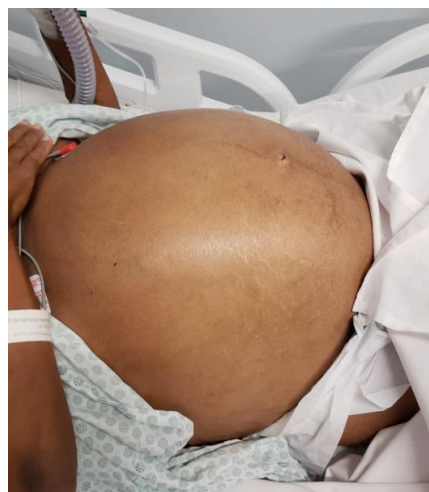The objective of this report is to evaluate the case of a patient with a large ovarian mass (12 kg) and an increased CA 125 tumor marker, whose histopathological examination showed a Brenner tumor associated with mucinous cystadenoma of the ovary. And also, discuss differential diagnoses, demonstrate the surgical treatment and clinical evolution of the patient in question.

The study was approved by CEP/EMESCAM, under opinion number 4,367,158. The patient signed an informed consent form giving her permission to publish this case report.

## ● CASE REPORT

A patient aged 47 years, G8 P6 A2, transpelvic deliveries, admitted to the emergency room of Holy House of Mercy of Vitória Hospital, presenting respiratory distress, dyspnea, pain and increased abdominal volume (image 1). On physical examination, the presence of a voluminous mass occupying the entire abdomen, poorly delimited and with a hardened consistency, was observed (Image 1).

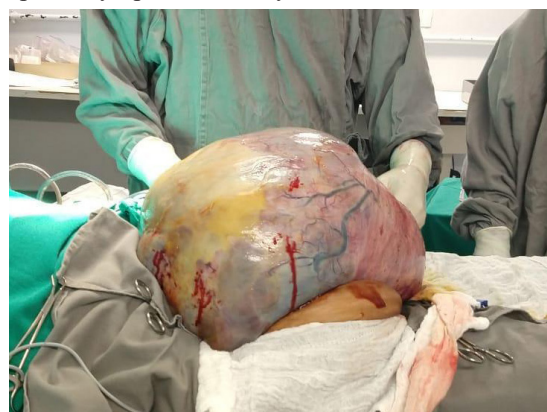She had a previous abdominal ultrasound, dated six months ago, showing moderate ascites and a voluminous cystic formation with coarse septations and debris, with solid areas occupying the entire abdominal cavity and displacing viscera, with an approximate volume of 4900 cm<sup>3</sup>. The investigation continued with tomography of the chest and abdomen, revealing the presence of pleural effusion on the right, associated with restrictive contact atelectasis, a small pericardial effusion and a voluminous mass, occupying a large part of the abdominal cavity, with cystic content and associated septa, measuring 38.2 x 30.2 x 28.2 cm and volume of 16,916 ml. Laboratory



**Image 1:** Patient's abdomen on admission

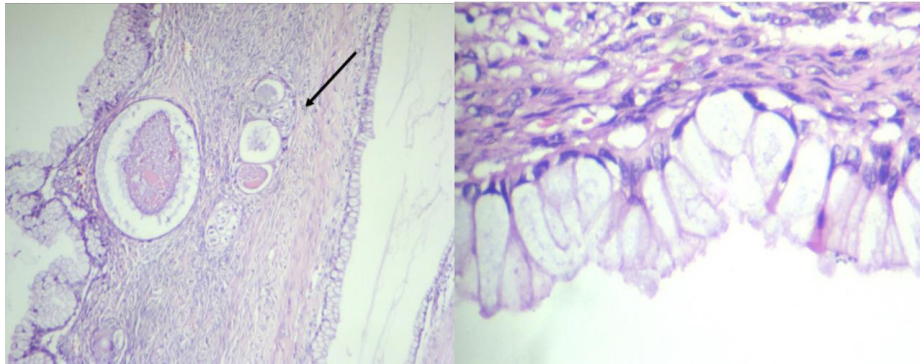
tests showed an increase in the tumor marker CA 125 (922 U/ml) and anemia (Hb 7.6 mg/dl and Ht 22.6 mg/dl). A thoracocentesis was performed, with drainage of 1,100 ml of liquid with a serohematic appearance in the right hemithorax, which was sent for cytological analysis, the result of which met Light's criteria<sup>5</sup> for transudate, therefore, excluding primary involvement of the pleura. It is associated with increased hydrostatic pressure, decreased oncotic pressure, decreased pressure in the pleural space or communication with the peritoneal cavity<sup>5</sup>.

After clinical stabilization, the patient underwent exploratory laparotomy, with a median xiphopubic incision, showing a large solid-cystic tumor, with multiple adhesions and mucinous-type peritoneal fluid. Peritoneal fluid was collected for cytology, tumor excision of approximately 34 x 27 cm and 12.1 kg (image 2), total hysterectomy, bilateral adnexectomy, peritoneal biopsy and pelvic lymphadenectomy.



**Image 2:** Tumor visualized intraoperatively, measuring 34 x 27 cm

The surgical specimen was sent for histopathology, whose result was compatible with a benign Brenner tumor (solid area) with a mucinous cystadenoma component (cystic area) of the ovary (image 3). No neoplastic involvement in uterus, tubes and right ovary. The results of oncotic cytology and peritoneal biopsy were negative for malignant neoplastic cells. The patient had a good postoperative evolution, being discharged from the hospital, with subsequent outpatient follow-up at the same service.



**Image 3:** Histopathology of the tumor, showing the Brenner's nests (arrow) and the mucinous cells (clear cytoplasmic epithelium that covers the tumor). HE,200X

### ● DISCUSSION

Brenner's tumor was first described as an adenofibroma-like tumor of the ovary by Macnaughton-Jones in 1898. In 1907, Fritz Brenner, after whom the tumor is named, believed that it was a variant of the granulosa tumor, and named it of follicular oophoroma. Finally, in 1932, Meyer introduced the name Brenner tumor<sup>6</sup>.

Transitional cell tumors represent approximately 1-2% of all ovarian tumors and include benign, borderline (proliferative) and malignant Brenner tumor and transitional cell carcinoma.

Histologically, Brenner tumors are fibroepithelial neoplasms made up of tissue derived from the ovarian stroma and epithelial cells, of the urothelial or transitional type. These cells have a small slit or "coffee bean"-shaped nucleus, and when they form groups, they form structures called niches or nests<sup>7</sup>.

Microscopically, mucinous cystadenomas resemble endocervical epithelium. They are usually more voluminous ovarian tumors, reaching 20 kg or more, establishing themselves, in these cases, as giant ovarian cysts. They tend to be multiloculated, cystic, unilateral, with mucoid content and brownish when cut. They are characterized by the secretion of mucinous and gelatinous material in large amounts<sup>8</sup>.

In 25% of the cases, Brenner's tumor can be associated with another ovarian tumor, as examples: mucinous, serous or endometrioid tumors<sup>9</sup>.

The coexistence of two adjacent, histologically distinct tumors in the same organ is called collision tumors by some authors. Knowing the association of these neoplasms is of both scientific and therapeutic interest, since the surgical approach can be modified in case of finding a malignant or borderline lesion<sup>10</sup>.

The conduct consists only of exeresis of the tumor, in benign cases. However, if the tumor is

malignant or suspected of malignancy, hysterectomy with bilateral oophorectomy is preferred, complemented by omentectomy, pelvic lymphadenectomy, biopsy and peritoneal lavage<sup>11</sup>.

This was the conduct for our patient, due to her perimenopausal status and the possibility of malignancy due to wasting syndrome, elevated CA 125 levels and suspicious ultrasound findings. Similar to the case reported by Farzaneh et al , in which a postmenopausal patient complaining of pain and increased abdominal volume, with imaging findings suggestive of a large adnexal tumor, underwent the same surgical treatment. The histopathological result was mucinous cystadenoma, associated with areas of Brenner's tumor<sup>12</sup>.

Baharak and collaborators reported the case of a patient also post-menopausal, presenting a progressively growing abdominal mass, about 20 cm, with low levels of CA 125 (37 U/ml) and other markers with normal titration. She underwent the same surgery described in this report, with exeresis of the mucinous tumor, however, with a microscopic finding of a Brenner tumor with a benign and malignant component<sup>13</sup>.

### ● CONCLUSION

The anatomopathological study revealed as diagnosis, a rare case of benign Brenner tumor associated with giant mucinous cystadenoma. The conduct should be based on histology: conservative, through intraoperative freezing, if benign, or radical conduct, if there is malignancy in one of the components. We conclude that, despite being rare, Brenner's tumor should be considered during the histopathological evaluation of large-volume ovarian tumors, such as mucinous cystadenoma. It is necessary to evaluate the possible malignancy of this component, which in many cases occupies a small percentage of the tumor, completely changing the surgical treatment and the patient's prognosis.

### ● REFERENCES

1. Carvalho FM. Câncer de ovário: história natural e anatomia patológica. In: Halbe HW editor. Tratado de Ginecologia. 3° ed. São Paulo: Roca; 2000. p. 2252-62.
2. Tavassoli FA, Devilee P. World Health Organization Classification of Tumours. Pathology and Genetics for Tumours of Breast and Female Genital Organs. Lyon. IARC Press, 2003; p. 140-3.
3. Lima GR, Lima AO, Baracat EC, Vasserman J, Burnier M Jr. Virilizing Brenner tumor of the ovary: case report. *Obstet Gynecol* 1989; 73:895-8.

4. Ming SC, Goldman H. Hormonal activity of Brenner tumors in postmenopausal women. *Am J Obstet Gynecol* 1962; 83: 666-73.
5. Junior CTS, Maranhão BHF, Chibante AMS, Cardoso GP. Novo critério bioquímico para classificar transudatos e exsudatos pleurais com dosagens de proteínas totais e desidrogenase lática somente no líquido pleural. *Pulmão RJ* 2016;25(1):29-32.
6. Landeyro J, Elguezabal A, Hijós MG, Boutayeb L, Garcia-Fontgivell JF, Estelle AR. Tumor de Brenner benigno bilateral asociado a cistoadenoma mucinoso. Una aproximación a lós tumores de células transicionales del ovario. *Rev. Esp. Patol.* 2011; 44(2): 83-87.
7. Chambô Filho A, Chambô D, Borges FLL, Cintra LC, Scardini R. Tumor de Brenner Benigno e Maligno na mesma paciente: Relato de caso. *Rev. Bras. Ginecol. Obstet.* 2002; 24(9): 625-628.
8. Resende GC, Benites GG, Calheiros AV, Mugayar Filho J, Oliveira LP, Siqueira OQK. Cistoadenoma ovariano gigante diagnosticado como ascite maciça. *Relatos Casos Cir.* 2017;(3).
9. Gedikbasi A, Ulker V, Aydin O, Akyol A, Numanoglu C, Ceylan Y. Brenner tumor in pregnancy: clinical approach and pathological findings. *J Obstet Gynaecol Res* 2009; 35:565-8.
10. Tiezzi DG, Guimarães EG, Oguido N, Nai GA. Cistoadenocarcinoma mucinoso de baixo potencial de malignidade em coexistência com teratoma cístico maduro do ovário: relato de caso. *Rev. Bras. Ginecol. Obstet.* 2003;25: 605-608.
11. Mondolfo R, Cavalieri A, Egami M. Tumor de Brenner: relato de um caso clínico e revisão da literatura. *Klinikos* 1988; 4:44-7.
12. Farzaneh N, Zahra D. Coexistence do benign Brenner tumor with mucinous cystadenoma in an ovarian massa. *Iran J Pathol.* 2020; 15(4): 334-337.
13. Khadang B, Omeroglu A. Ovarian Mixed Malignant Brenner-Mucinous Tumor with Signet Ring Cells. *Case Rep Pathol.* 2020;2020:2134546.

### Resumo

**Objetivo:** O tumor de Brenner é uma neoplasia ovariana rara, representando apenas 1-2% das neoplasias de ovário, sendo em sua maioria, tumores benignos. É definida como uma neoplasia fibroepitelial derivada do tecido estromal ovariano e por células epiteliais do tipo urotelial ou de transição. Raramente possuem manifestações clínicas, visto que são pequenos e unilaterais. Entretanto, há relatos na literatura de tumores com grandes dimensões. Em 25% dos casos, o tumor de Brenner pode estar associado a outro tipo de tumor ovariano, como por exemplo tumores mucinosos, serosos ou endometrióides. A conduta frequentemente constitui-se apenas de exérese do tumor, em casos benignos. Todavia, se tumor maligno ou suspeita de malignidade, a histerectomia com salpingooforectomia bilateral é preferida, complementada pela omentectomia, linfonodectomia pélvica, biópsia e lavado peritoneal.

**Palavras-chave:** tumor de Brenner; cistoadenoma mucinoso; neoplasia ovariana; ovário